

## Advanced osteoradionecrosis of the maxilla: a 15-year, single-institution experience of surgical management

Zimeng Li , Shangping Liu , Shang Xie , Xiaofeng Shan , Lei Zhang & Zhigang Cai

To cite this article: Zimeng Li , Shangping Liu , Shang Xie , Xiaofeng Shan , Lei Zhang & Zhigang Cai (2020) Advanced osteoradionecrosis of the maxilla: a 15-year, single-institution experience of surgical management, Acta Oto-Laryngologica, 140:12, 1049-1055, DOI: [10.1080/00016489.2020.1812714](https://doi.org/10.1080/00016489.2020.1812714)

To link to this article: <https://doi.org/10.1080/00016489.2020.1812714>



Published online: 12 Sep 2020.



Submit your article to this journal [↗](#)



Article views: 28

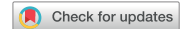

View related articles [↗](#)



View Crossmark data [↗](#)

RESEARCH ARTICLE



## Advanced osteoradionecrosis of the maxilla: a 15-year, single-institution experience of surgical management

Zimeng Li<sup>a</sup>, Shangping Liu<sup>b</sup>, Shang Xie<sup>a</sup>, Xiaofeng Shan<sup>a</sup>, Lei Zhang<sup>a</sup> and Zhigang Cai<sup>a</sup>

<sup>a</sup>Department of Oral and Maxillofacial Surgery, National Engineering Laboratory for Digital and Material Technology of Stomatology, Beijing Key Laboratory of Digital Stomatology, Peking University School and Hospital of Stomatology, Beijing, P. R. China; <sup>b</sup>The Third Dental Center, Peking University School and Hospital of Stomatology, Beijing, P. R. China

### ABSTRACT

**Background:** Osteoradionecrosis (ORN) of the maxilla is a rare disease. In contrast with a mandibular predominance, maxillary ORN has not been widely reported.

**Objective:** To review clinical features, surgical treatments, and results of maxillary ORN and offer recommendations for surgical decision-making.

**Material and methods:** We retrospectively reviewed medical records of maxillary ORN at our hospital between 2002 and 2017. Clinical data were collected, including age, sex, primary tumor characteristics, radiotherapy dose, clinical findings of maxillary ORN, and treatment outcomes. Descriptive statistics and multiple factors were analyzed.

**Results:** Twenty-four patients were included for analysis. The primary symptoms of maxillary ORN were pain, trismus, pus, bone exposure, and skin fistula. Twenty (83.3%) patients were completely cured after single-operation. Thirteen patients underwent sequestrectomy, and the cure rate was 76.9% (10/13). Eleven patients received segmental osteotomy and flap reconstruction, with the cure rate of 90.9% (10/11). There was no significant statistical difference in the cure rate between these two groups ( $p = .596$ ).

**Conclusions and significance:** Compared with mandibular ORN, the surgical effect of maxillary lesions is better and the choice of operation methods can be relatively conservative. Both sequestrectomy and segmental osteotomy with flap reconstruction can achieve good results in appropriate conditions.

### ARTICLE HISTORY

Received 26 May 2020

Accepted 14 August 2020

### KEYWORDS

Osteoradionecrosis of maxilla; surgical treatments; sequestrectomy; vascular flap reconstruction; prognosis

### Introduction

Radiotherapy as a primary, adjuvant, or palliative therapy is used in approximately 75% of patients with head and neck cancer (HNC), which significantly improves therapeutic efficiency [1,2]. However, radiotherapy can also frequently lead to negative effects, including mucositis, xerostomia, dysgeusia, dental caries, and osteoradionecrosis (ORN) [3]. ORN of the jaws (ORNJ) is one of the most devastating and refractory consequences after irradiation for HNC and severely affect patients' quality of life.

In early studies, ORNJ was considered as radiotherapy-induced bone marrow inflammation, and hence, was termed radioactive osteomyelitis. However, with reports of antibiotic ineffectiveness and a deeper understanding, such lesions were identified as irreversible degeneration of bone tissue.

Since Regaud first reported ORNJ in 1922, voluminous literature on ORN of the mandible has been reported, covering etiology, clinical characteristics, risk factors, and treatment strategies. In contrast, perhaps because the incidence of maxillary ORN is significantly lower than that of mandibular ORN [4], the number of reports on maxillary ORN is small. As mentioned previously, the primary tumor types

were mainly nasopharyngeal carcinoma (NPC), whereas maxillary ORN caused by radiotherapy for other types of HNC were rarely reported. Although surgical methods are recommended in advanced cases, there is no clear indication for the choice of surgery corresponding to the different stages of maxillary ORN. Therefore, in this study, to help establish the optimal surgical treatment for maxillary ORN, the medical history of patients who visited our hospital was retrospectively reviewed. We investigated the clinical features, surgical methods, and treatment outcomes, and documented our clinical experience of this disease.

### Methods

This study adhered to the tenets of the Declaration of Helsinki and was approved by the Regional Ethical Review Board of our hospital. Written informed consent was obtained from all patients.

The study cohort comprised consecutive patients with maxillary ORN who were admitted to the Department of Oral and Maxillofacial Surgery in our hospital, from January 2002 to December 2017. The ORN diagnostic criteria were

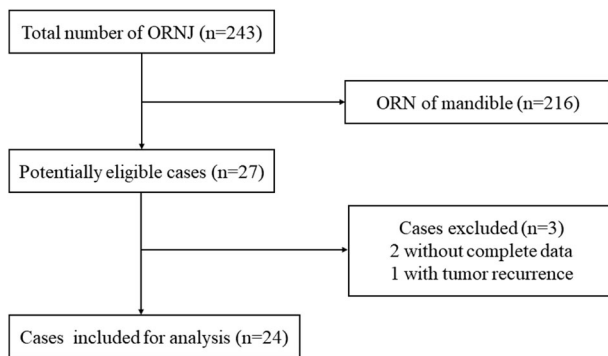


Figure 1. Flow diagram of included and excluded cases.

as follows: (1) definite history of radiotherapy for HNC; (2) bone exposure that failed to heal for at least 3 months or radiological evidence of bony destruction; (3) postoperative pathological diagnosis of osteoradionecrosis and no primary tumor recurrence; and (4) no history of bisphosphonate use [5,6]. Only patients with maxillary ORN who underwent surgical treatments were eligible for inclusion. These patients received conservative treatments (oral care, pentoxifylline and tocopherol, HBO, etc.) before but were ineffective and the disease advanced. Patients were excluded if complete clinical data were unavailable.

Two groups (NPC and oral malignant tumor) were divided according to the primary tumors, so the characteristics of maxillary ORN after the radiotherapy of different oncology could be analyzed. The patients were divided into another two groups according to different surgical methods: sequestrectomy and segmental osteotomy. We chose the operation method relatively conservative and mainly according to the soft tissue condition and the pattern of dead bone in the X-ray image: patients primarily underwent sequestrectomy in good soft tissue status and clear dead bone boundary; on the contrary, the segmental osteotomy and flap reconstruction was performed in patients with poor soft tissue and extensive diffuse dead bone. We regard the integrity of oral mucous membrane and skin as good soft tissue status, and intraoral mucosal or external skin fistula as poor soft tissue status [7]. In sequestrectomy, the dead bone was entirely removed by scraping the bone until only fresh blood was seen and the wounds were directly sutured. In segmental osteotomy, the dead bone was removed by wide excision and the defect was closed using a vascularized or pedicled flap.

The related clinical data, including demographic information, clinical oncologic history, total radiotherapy dose, ORN symptoms presented, and hospital admission details were recorded. The patients were followed up at the outpatient department every three months for the first year; the interval was gradually increased afterward. Computed tomography was performed every 6 months, and any changes in the clinical symptoms were recorded. The therapeutic effect was recorded as 'resolved' and 'unhealed'. 'Resolved' indicated that the patient was asymptomatic (no pain, dead bone exposure, fistula, and pus) with recovered or improved function (mouth opening > 2cm, and masticatory function

Table 1. Demographic and clinical characteristics of patients with maxillary ORN (N = 24).

Variables	Number	Percentage (%)
Sex		
Male	17	70.8
Female	7	29.2
Age (years)		
Mean $\pm$ SD	53 $\pm$ 10.9	–
Median	53	–
Range	31–74	–
Smoking	9	37.5
Alcohol consumption	5	20.8
DM2	7	29.2
Tooth extraction	5	20.8
ORN sites		
Maxilla alone	17	70.8
Multiple maxillofacial bones	7	29.2
Symptoms		
Pain	18	75
Trismus	16	66.7
Pus	13	54.2
Sequestrum exposure	9	37.5
Skin fistula	7	29.2
Time <sup>a</sup> (months)		
Mean $\pm$ SD	55.1 $\pm$ 68	–
Median	22	–
Range	2–270	–

DM2: diabetes mellitus type 2; ORN: osteoradionecrosis; SD: standard deviation.

<sup>a</sup>Time from the end of radiotherapy to the diagnosis of ORN.

improvement), and 'unhealed' indicated that symptoms were not resolved or deteriorated.

SPSS 24 (IBM Corp., Armonk, NY, USA) was used for statistical analysis. Descriptive statistical analysis was performed as the initial step. Continuous quantitative variables are presented as mean  $\pm$  SD, median, minimum and maximum values, and qualitative variables are presented as frequencies (N) and relative distributions (%). Categorical variables were analyzed using Fisher's exact test; continuous variables were analyzed using the unpaired Student's t-test.  $p < .05$  was considered statistically significant.

## Results

During the study period, 243 patients were treated for ORN]; of these, 216 showed ORN in the mandibular, 2 cases did not have complete clinical data, and 1 had tumor recurrence. Thus, 24 patients (17 men [70.8%]; age: 31–74 years; median age: 53 years) were included for the final analysis (Figure 1). In 17 (70.8%) patients, ORN was detected only in the maxilla; in 7 (29.2%) patients, ORN was detected simultaneously in the maxilla and other maxillofacial bones (zygoma: three cases, mandible: four cases). The most commonly reported symptom was pain ( $n = 18$ , 75%), followed by trismus ( $n = 16$ , 66.7%). The basic demographic and clinical characteristics of the patients are presented in Table 1. The most common site for primary tumors was the nasopharynx ( $n = 10$ , 41.7%), and most patients ( $n = 19$ , 79.1%) received radiotherapy for squamous cell carcinoma. Three patients with NPC received multiple sessions of radiotherapy, whereby a patient with a radiation dose of 120 Gy received the second course 13 years after the first due to tumor recurrence, and the dose was included in

**Table 2.** Data of the primary tumors ( $N=24$ ).

	Number	Percentage (%)
Site of primary tumors		
Nasopharynx	10	41.7
Gingiva	4	16.7
Maxillary sinus	4	16.7
Palate	3	12.5
Buccal mucosa	2	8.3
Tongue	1	4.2
Primary tumor pathology		
SCC	19	79.1
ACC	4	16.7
Lymphoma	1	4.2
Overall treatment		
Surgery with radiotherapy	14	58.3
Radiotherapy alone	10	41.7
RD (Gy)		
Mean $\pm$ SD	73.7 $\pm$ 17.7	–
Median	70	–
Range	58–120	–

SCC: squamous cell carcinoma; ACC: adenoid cystic carcinoma; RD: radiation dose; SD: standard deviation.

the calculation. The primary tumor data are presented in Table 2.

According to the primary tumor, we divided the patients into the oral malignant tumor and NPC groups. After univariate analysis of the variables, the results revealed significant intergroup differences in the radiation dose ( $p = .018$ ) and surgery before radiotherapy ( $p = .003$ ). The irradiation dose was higher in the NPC group than in the oral malignant tumor group; more patients in the latter underwent an operation before radiotherapy. Intergroup differences in sex, age, ORN sites, tooth extraction after RT, and radiation to diagnosis time were not significant ( $p > .05$ ) (Table 3).

Sequestrectomy ( $n = 13$ , 54.2%) and segmental osteotomy ( $n = 11$ , 45.8%) were used as the resection methods, and all patients who received segmental osteotomy underwent flap reconstruction simultaneously. The most used flap in segmental osteotomy group was the anterolateral thigh flap (7/11 cases, 63.6%), followed by the radial forearm flap (2/11 cases, 18.2%). Other soft-tissue pedicled flaps such as the pectoralis major myocutaneous flap (1/11, 9.1%) and submental island flap (1/11, 9.1%) were also used. In the nine cases with vascularized free flaps, the most commonly used recipient artery was the facial artery (5/9, 55.6%), followed by the superior thyroid artery (3/9, 33.3%) and lingual artery (1/9, 11.1%). The recipient veins were the external jugular vein (5/9, 55.6%) and internal jugular vein (4/9, 44.4%).

Postsurgical complications reported immediately included venous vascular crisis in one case (1/11, 9.1%) and postoperative bleeding in another (1/24, 4.2%). These two patients underwent unplanned reoperations immediately to manage the complications. Since the flap returned to normal after exploratory surgery, the total vascularized flap success rate was 100%.

All 24 patients were followed up for at least 1 year, and treatment outcomes were available. Complete resolution occurred in 20 patients after one surgery; the single-operation cure rate was 83.3% in this cohort. Four (16.7%) had wound infections with the sequestrum exposed again. Two of them eventually recovered after multiple debridement

**Table 3.** Clinical features in the different primary tumor groups ( $N=24$ ).

	NPC ( $n=10$ )	OMT ( $n=14$ )	$p$
Sex			
Male	7 (70%)	10 (71.4%)	1.000
Female	3 (30%)	4 (28.6%)	
Age (years), mean $\pm$ SD	51.3 $\pm$ 9.3	54.2 $\pm$ 12.1	.523
ORN sites			
Maxilla alone	7 (70%)	10 (71.4%)	1.000
Multiple maxillofacial bones	3 (30%)	4 (28.6%)	
Surgery before RT	2 (20%)	12 (85.7%)	.003
Tooth extraction after RT	4 (40%)	1 (7.1%)	.303
RD (Gy); mean $\pm$ SD	83.6 $\pm$ 23.5	66.7 $\pm$ 6.8	.018
Time <sup>a</sup> (months); mean $\pm$ SD	62.2 $\pm$ 65.1	50 $\pm$ 72	.677

NPC: nasopharyngeal carcinoma; OMT: oral malignant tumors; ORN: osteoradiation necrosis; RT: radiotherapy; RD: radiation dose; SD: standard deviation.

$p < .05$  was considered statistically significant.

<sup>a</sup>Time from the end of radiotherapy to the diagnosis of ORN.

under local anesthesia and wound irrigation; one patient suffered from a long period of nonunion of wound, and then he underwent segmental osteotomy and anterolateral thigh flap reconstruction and recovered; one gave up further treatment and were lost to follow-up one year after surgery. Therefore, a total of 23 patients were eventually cured, with the long-term overall cure rate of 95.8% (23/24).

To analyze the single-operation outcomes of the different treatment methods, we divided the patients into the sequestrectomy and segmental osteotomy with flap reconstruction groups, and univariate analysis of multiple independent variables was performed. The cure rates of single-operation were 76.9% (10/13) in the sequestrectomy and 90.9% (10/11) in segmental osteotomy groups; intergroup differences were not significant ( $p = .596$ ). The results revealed significant intergroup differences in the lesion location ( $p = .023$ ), soft tissue status ( $p = .021$ ) and hospitalization duration ( $p = .000$ ). Only a few patients in the sequestrectomy group had lesions on multiple maxillofacial bones; scattered lesions were noted in the segmental osteotomy group. The soft tissue condition of patients in the sequestrectomy group was significantly better than segmental osteotomy group. The hospital stay in the latter group was significantly longer. And there was no significant statistical difference in other variables (Table 4).

## Discussion

For patients with HNC who have received radiotherapy, ORNJ is one of the most serious complications. According to a previous systematic review, the incidence of ORN ranged from 4.74% to 37.5% [8]. Recent data have shown that the incidence of ORN is decreasing, which may due to the greater emphasis on oral examination and the application of updated radiotherapy methods such as intensity-modulated radiation therapy (IMRT) [8]. Since radiotherapy cannot be carried out in our hospital, patients with HNC received radiation at other different medical institutions, so the exact ORN incidence rate and radiotherapy technique could not be determined in this study.

The proportion of mandibular ORN is significantly higher than maxillary ORN [4]. Some authors believe that the main cause of this predilection is the single blood supply

**Table 4.** Clinical features and prognosis in the different treatment groups (N = 24).

	Sequestrectomy (n = 13)	Segmental osteotomy (n = 11)	<i>p</i>
Sex			
Male	9 (69.2%)	8 (72.7%)	1.00
Female	4 (30.8%)	3 (27.3%)	
Age (years), mean ± SD	50.4 ± 11.9	56.1 ± 9.2	.218
DM2			
Yes	3 (23.1%)	4 (36.4%)	.659
No	10 (76.9%)	7 (63.6%)	
ORN sites			
Maxilla alone	12 (92.3%)	5 (45.5%)	.023
Multiple maxillofacial bones	1 (7.7%)	6 (54.5%)	
Soft tissue status			
Good <sup>a</sup>	11 (84.6%)	4 (36.4%)	.021
Poor <sup>b</sup>	2 (8.3%)	7 (63.6%)	
Dead bone pattern			
Clear boundary	8 (61.5%)	3 (27.3%)	.123
Diffuse	5 (38.5%)	8 (72.7%)	
RD (Gy); mean ± SD	72.7 ± 16.1	74.9 ± 20.2	.776
Hospital stay (days)	6.2 ± 0.9	10.2 ± 1.6	.000
Time <sup>c</sup> (months); mean ± SD	57.2 ± 84.5	56 ± 45.4	.873
Treatment outcome			
Unhealed	3 (23.1%)	1 (9.1%)	.596
Resolved	10 (76.9%)	10 (90.9%)	

DM2: diabetes mellitus type 2; ORN: osteoradionecrosis; RD: radiation dose; SD: standard deviation.

*p* < .05 was considered statistically significant.

<sup>a</sup>Good soft tissue status: integrity of oral mucous membrane and skin.

<sup>b</sup>Poor soft tissue status: intraoral mucosal or external skin fistula.

<sup>c</sup>Time from the end of radiotherapy to the diagnosis of ORN.

pattern of the mandible [4], while others deem that the mandible is located in the target area more frequently in HNC radiotherapy schemes involving a large dose of radiation [5]. The mandible contains more cortical bone components, which leads to poor self-healing ability compared with maxilla after injury. Consistent with the previous reports, a total of 243 ORNJ patients visited our hospital in our study, of which 216 patients showed ORN in the mandible.

High radiation dose is a definite risk factor for the occurrence of ORNJ, yet the previous studies were mainly about ORN occurring in the mandible or both jaws. Lee et al. [9] suggested that a radiation dose higher than 54 Gy was sufficient to cause mandibular ORN. Thorn et al. [4] reported that 2.5% of patients with ORNJ received radiotherapy less than 50 Gy, and 60–68 Gy is the main range of the radiation dose. In the present study, the enrolled maxillary ORN patients received average dose of 73.7 Gy, which was slightly higher than the previous reports. These findings could be explained by the fact that the radiation dose in this study was the total dose, and the radiation dose received by maxilla alone cannot be calculated accurately. In addition, three of our patients received multiple sessions of radiotherapy, and the total dose before the onset of ORN was included in the calculation. Logically, the maxilla may be resistant to higher doses of radiotherapy than the mandible, considering the greater cancellous bone and more abundant bloody supply in the maxilla [8]. Meanwhile, it is noted that the minimum radiation dose in the study was only 52 Gy. We believe that the radiation dose should be considered as a reference but not an exact predictor, because factors such as tooth extraction, smoking, and diabetes affect the risk as well [10].

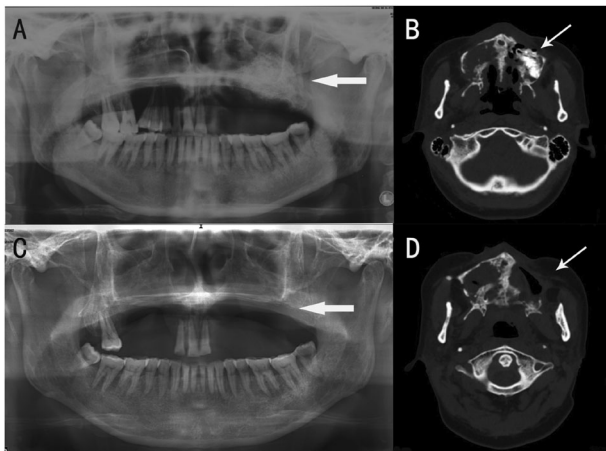
Previous studies have provided much information about the influence of primary tumor characteristics on the

occurrence of ORNJ. Some scholars hold that NPC patients who receive radiation treatment seem to have higher ORN risk in the maxilla than in the mandible [11]. Similarly, Cheng et al. demonstrated that the incidence of maxillary ORN was 2.7%, with a total ORNJ incidence of 3.5% in 1758 irradiated NPC patients [12]. In our study, we assessed 10 patients whose primary tumor was NPC, and the primary tumors of the other 14 patients were oral malignant tumors, with a ratio of 1:1.4. The primary tumor predilection of maxillary ORN patients was not significant (*p* > .05).

Radiotherapy is generally the first choice for NPC, while it is an adjuvant therapy for oral malignant tumors. The present study showed a significant difference between the number of NPC patients and oral malignant tumor patients who underwent surgery before radiotherapy (*p* = .003), and the number of NPC patients was smaller than oral malignant tumors group. Meanwhile, the irradiation dose for NPC patients was significantly higher than oral malignant tumor patients (*p* = .018). Most patients with relapsed oral cancer underwent reoperation if they showed indications for surgery, and three patients with recurrent NPC received repeated radiotherapy. The blood supply of maxilla may be damaged by the surgery before radiotherapy, which will result in reduction of radiation resistance [13]. This may be a risk factor that reduces the trigger radiation dose and increases the proportion in patients with oral malignant tumors.

A classification system that can guide clinical practice and evaluate prognosis is undoubtedly important. Granzmann et al. [14] proposed classification systems for mandibular ORN, but it have not been proved to have clinical applicability [11]. Other staging systems have been developed to assist in guiding therapeutic regimens [5,7,15]; however, none of them can be applied to the maxilla. Based on the degrees of bone exposure, infection, and bleeding,



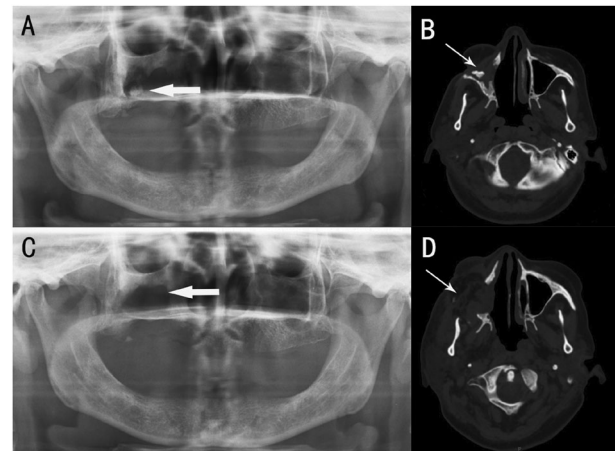


**Figure 2.** Imaging findings of a 45-year-old woman who refused to accept flap surgery and underwent sequestrectomy. The primary tumor of the patient was palate ACC, and she received 70Gy of radiation. The clinical symptoms were oral mucosal fistula, exposure of sequestrum, and pus drainage. (A and B) Before surgery: large high-density sequestrum observed in the left maxillary region (indicated by thick and thin arrows). (C and D) Three years after surgery: good healing without obvious progression of the lesion (thick and thin arrows).

Cheng et al. proposed a scoring system (EIB) for maxillary ORN caused by NPC radiotherapy in 2006 [12]. To date, there is no universally recognized classification system for maxillary ORN. As a rare disease, there were only 24 cases of maxillary ORN in this study. Furthermore, we mainly receive patients in the advanced stage as a surgical department. Accordingly, it is insufficient to propose a new scoring system for maxillary ORN in our study.

Despite the present controversy over the grading system of maxillary ORN, it is recognized that complete removal of necrotic bone and soft tissue is a key requirement in the surgical treatment of ORN [15,16]. Compared with ORN of mandible, the healing of maxillary ORN after surgery is likely to be more pleasant. As reported in 2014 [17], for ORN patients (including maxilla and mandible), the cure rate of conservative treatment was 45.3%, while the cure rate of the surgical approach after conservative treatment failure was approximately 40%. On the contrary, Cheng et al. reported that the cure rate of maxillary ORN in their 48 patients was 82.5% [12], and all the 12 cases treated by microvascular free flaps were cured in the study by Coskunfirat et al. [13]. Similarly, in the present cohort, the single-operation cure rate of maxillary ORN was 83.3%, with the long term cure rate of 95.8%.

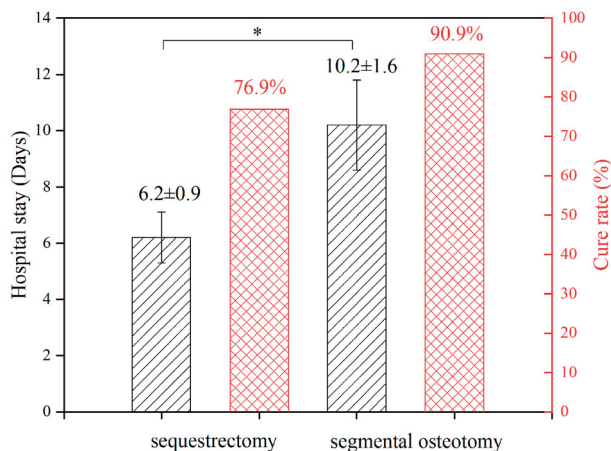
Two types of resection methods, sequestrectomy and segmental osteotomy, were primarily used in this study, and the patients were divided into these two groups. Figure 2 and Figure 3 show images of representative patients treated by the two methods. For patients with clear dead bone boundary and good soft tissue condition, sequestrectomy was preferred in our clinical practice. The segmental osteotomy with flap reconstruction was performed in poor soft tissue and extensive diffuse dead bone conditions. The results demonstrated that the soft tissue condition of the sequestrectomy group was significantly better than that of segmental osteotomy group ( $p = .021$ ). Although there was no significant difference between the two groups in the



**Figure 3.** Imaging of resection with segmental osteotomy and reconstruction with a submental island flap in a 61-year-old woman. The primary tumor was an NPC, and the patient received 60Gy of radiation. The clinical symptoms were extreme pain, trismus, oral mucosal fistula, and exposure of the sequestrum. (A and B) Before surgery: extensive irregular bone destruction in the right maxillary area with a small high-density sequestrum in the range (indicated by thick and thin arrows). (C and D) One year after surgery: no obvious disease progression or dead space was found (thick and thin arrows).

pattern of dead bone ( $p = .123$ ), the clear boundary type of dead bone in the sequestrectomy group (61.5%) and the diffuse type in the segmental osteotomy group (72.7%) accounted for the majority. These results were in line with our clinical practice of operative selection. Under such consideration of surgical choice, there was no significant statistical difference in the cure rate between these two groups ( $p = .596$ ). The results also revealed significant intergroup differences in the hospitalization duration ( $p = .000$ ), and the segmental osteotomy group was significantly longer than that in the sequestrectomy group (Figure 4). In addition, unlike mandibular ORN, the progress of maxillary ORN is relatively slow, and some patients can even maintain stability for a long period without any complications [12]. Accordingly, we tend to be conservative for the choice of surgical methods, and it was suggested that sequestrectomy could be the first option in the maxillary ORN patients who have good soft tissue conditions and clear dead bone boundary. If the wound heals completely after the minor operation, the surgical trauma, pain, and financial burden will be significantly reduced. However, it is not recommended to narrow the scope of resection to reduce the surgical trauma. It should be also noted that some patients may show local tumor recurrence in the lesion of ORN. Biopsy should be performed on the suspected tissue during operation, and sequestrectomy is not recommended if tumor relapse is proved.

Nevertheless, when maxillary ORN involved multiple bones, the first choice of surgery was more likely to be segmental osteotomy plus flap reconstruction ( $p = .023$ ). Among the seven cases with multiple bone lesions, three involved the zygomatic bone. The main blood supply of the zygoma is *via* the maxillary artery, and it can be affected by the operation on maxilla, which may be one of the main causes of zygomatic ORN [13]. Due to the prominent position, it can no longer form effective soft tissue coverage once the zygoma is exposed, which was considered that they



**Figure 4.** Statistical comparison of hospitalization time and cure rate between the sequestrectomy and segmental osteotomy groups.

had poor soft tissue condition. Therefore, we chose segmental osteotomy and flap repair as the surgical method for all patients with zygomatic exposure. On the other hand, the maxilla is adjacent to the skull base, with many major nerves and blood vessels around it. If maxillary ORN progresses, the skull base can be easily affected, which may lead to central nervous infection or even fatal bleeding [18]. Therefore, it is necessary to perform flap surgery when the important positions (pterygomandibular space, skull base, etc.) are affected by maxillary ORN.

Sufficient vascularized tissue will provide complete coverage to the key areas to avoid further infection and exposure of major blood vessels, so flaps with abundant tissue are more suitable for this purpose. The pedicled flap is not the best option compared with vascularized flap for ORN, because it cannot provide sufficient vascular pedicle, flexibility and reliable blood supply to the radiated area [16,19]. Among the microvascular soft tissue flaps, the anterolateral thigh flap (ALTF) is the most commonly used flap for almost all types of soft tissue defects in the head and neck [13], and it is the flap that we recommend for the reconstruction of maxillary ORN. Consistent with the previous literature, the number of ALTFs was the largest, with seven cases accounting for 63.6% of the total number of flaps. We also used radial forearm flap to repair the superficial bone defect without large dead spaces. In comparison with bone reconstruction, procedures based on soft tissue flaps are relatively convenient, with acceptable aesthetic and functional results [20].

Currently, free fibular flap is the most widely used vascularized bone flap. However, titanium plates exposure is a common complication after bone flap reconstruction. Fibrosis in the soft tissue makes the texture more fragile after radiation therapy, and hard material stimulation is prone to cause wounds that are difficult to heal. Furthermore, because most maxillary ORN patients show less impairment in shape and function than the mandible, we do not recommend vascularized bone flaps as the first choice for maxillary ORN reconstruction. For young patients with good physical condition and tumor prognosis, the vascularized bone flap may be a feasible attempt that needs further study.

## Conclusion

ORNJ is the most serious consequence for patients who have received radiotherapy to the head and neck region. In contrast with a mandibular predominance, maxillary ORN has not been widely reported. Surgical treatment is the mainstay for maxillary ORN treatment. Resection and reconstruction methods should be selected after careful evaluation of the soft tissue status, extent of dead bone, and the patients' physical condition. Sequestrectomy should be used in the patients who have limited lesions and good soft tissue status. When patients have poor soft tissue with extensive diffuse dead bone or sequestrectomy was ineffective, segmental osteotomy with flap reconstruction was necessary. Our limited clinical results showed that both sequestrectomy and segmental osteotomy with flap reconstruction can achieve good results in appropriate conditions.

## Disclosure statement

No potential conflict of interest was reported by the author(s).

## Funding

This study was supported by The National Key Research and Development Program of China [grants No. 2016YFC1102902], Beijing Municipality Development Foundation [grants No. Z161100000516016].

## References

- [1] Barton MB, Jacob S, Shafiq J, et al. Estimating the demand for radiotherapy from the evidence: a review of changes from 2003 to 2012. *Radiother Oncol.* 2014;112(1):140–144.
- [2] Gregoire V, Langendijk JA, Nuyts S. Advances in radiotherapy for head and neck cancer. *J Clin Oncol.* 2015;33(29):3277–3284.
- [3] Bentzen SM. Preventing or reducing late side effects of radiation therapy: radiobiology meets molecular pathology. *Nat Rev Cancer.* 2006;6(9):702–713.
- [4] Thorn JJ, Hansen HS, Specht L, et al. Osteoradionecrosis of the jaws: clinical characteristics and relation to the field of irradiation. *Journal of oral and maxillofacial surgery: official journal of the American Association of Oral and Maxillofacial Surgeons.* 2000;58(10):1088–1093. discussion 1093–5.
- [5] Epstein JB, Wong FL, Stevenson-Moore P. Osteoradionecrosis: clinical experience and a proposal for classification. *J Oral Maxillofac Surg.* 1987;45(2):104–110.
- [6] Owosho AA, Kadempour A, Yom SK, et al. Radiographic osteoradionecrosis of the jaw with intact mucosa: proposal of clinical guidelines for early identification of this condition. *Oral Oncol.* 2015;51(12):e93–e96.
- [7] He Y, Liu Z, Tian Z, et al. Retrospective analysis of osteoradionecrosis of the mandible: proposing a novel clinical classification and staging system. *Int J Oral Maxillofac Surg.* 2015;44(12):1547–1557.
- [8] Nabil S, Samman N. Risk factors for osteoradionecrosis after head and neck radiation: a systematic review. *Oral Surg Oral Med Oral Pathol Oral Radiol.* 2012;113(1):54–69.
- [9] Lee IJ, Koom WS, Lee CG, et al. Risk factors and dose-effect relationship for mandibular osteoradionecrosis in oral and oropharyngeal cancer patients. *Int J Radiat Oncol Biol Phys.* 2009;75(4):1084–1091.

- [10] Sathasivam HP, Davies GR, Boyd NM. Predictive factors for osteoradionecrosis of the jaws: a retrospective study. *Head Neck*. 2018;40(1):46–54.
- [11] Jereczek-Fossa BA, Orecchia R. Radiotherapy-induced mandibular bone complications. *Cancer Treat Rev*. 2002;28(1):65–74.
- [12] Cheng SJ, Lee JJ, Ting LL, et al. A clinical staging system and treatment guidelines for maxillary osteoradionecrosis in irradiated nasopharyngeal carcinoma patients. *Int J Radiat Oncol Biol Phys*. 2006;64(1):90–97.
- [13] Coskunfirat OK, Wei FC, Huang WC, et al. Microvascular free tissue transfer for treatment of osteoradionecrosis of the maxilla. *Plast Reconstr Surg*. 2005;115(1):54–60.
- [14] Glanzmann C, Gratz KW. Radionecrosis of the mandibula: a retrospective analysis of the incidence and risk factors. *Radiother Oncol*. 1995;36(2):94–100.
- [15] Notani K, Yamazaki Y, Kitada H, et al. Management of mandibular osteoradionecrosis corresponding to the severity of osteoradionecrosis and the method of radiotherapy. *Head Neck*. 2003;25(3):181–186.
- [16] Shaha A, Cordeiro P, Hidalgo D, et al. Resection and immediate microvascular reconstruction in the management of osteoradionecrosis of the mandible. *Head Neck*. 1997;19(5):406–411.
- [17] Zaghi S, Danesh J, Hendizadeh L, et al. Changing indications for maxillomandibular reconstruction with osseous free flaps: a 17-year experience with 620 consecutive cases at UCLA and the impact of osteoradionecrosis. *Laryngoscope*. 2014;124(6):1329–1335.
- [18] Li JH, Peh WC, Sham JS. Maxillary osteonecrosis after radiotherapy for nasopharyngeal carcinoma. *Clin Oncol*. 1994;6(2):135–136.
- [19] Baker SR. Management of osteoradionecrosis of the mandible with myocutaneous flaps. *J Surg Oncol*. 1983;24(4):282–289.
- [20] Chang D, Oh H, Robb G, et al. Management of advanced mandibular osteoradionecrosis with free flap reconstruction. *Head Neck*. 2001;23(10):830–835.